

Case Report *Pediatric Ophthalmology and Strabismus*

A rare case of X-linked hypohidrotic ectodermal dysplasia with chorioretinal lesions by missense mutation in ectodysplasin A gene from Northeast India

Nilutparna Deori¹, Madhusmita Mahapatra², Dipankar Das³, Manjisa Choudhury⁴

Departments of ¹Pediatrics Ophthalmology and Strabismus, ²Ophthalmology, ³Ocular Pathology, Uveitis and Neuro-Ophthalmology, ⁴Indian Ophthalmology Clinical Trial Network, BIRAC Project, Sri Sankaradeva Nethralaya, Guwahati, Assam, India.



***Corresponding author:**

Nilutparna Deori,
Department of Pediatric
Ophthalmology and
Strabismus, Sri Sankaradeva
Nethralaya, Guwahati, Assam,
India.

nilutparnadeori@gmail.com

Received: 05 June 2024
Accepted: 20 August 2024
EPub Ahead of Print: 21 November 2024
Published: 21 December 2024

DOI
10.25259/JORP_22_2024

Quick Response Code:



ABSTRACT

Hypohidrotic ectodermal dysplasia (HED) is a rare genetic condition affecting 1–7 cases in 10,000 live births. It is the most common type of ectodermal dysplasia. Here, we report a case of X-linked HED with missense mutation in ectodysplasin A gene with choroiditis lesion.

Keywords: Ectodermal dysplasia, Ectodysplasin A gene, Sanger sequencing, X-linked hypohidrotic ectodermal dysplasia

INTRODUCTION

Hypohidrotic ectodermal dysplasia (HED) typically follows – the X-linked, autosomal recessive, and autosomal dominant patterns of inheritance, among which X-linked HED (XLHED) is the most common type of ectodermal dysplasia. HED is characterized by sparse or absent eccrine glands as well as hypotrichosis and oligodontia with peg shaped teeth. HED can result from mutations in one of the several genes – ectodysplasin A (EDA), EDA receptor (EDAR), and EDAR associated death domain (EDARADD). EDA is the only known gene to be associated with XLHED and about 95% of individuals with HED are diagnosed with the X-linked form.^[1]

CASE REPORT

A 14-year-old male presented with complaints of photophobia and watering in both eyes (OU) for the past couple of months. On examination, the boy had features of dry eyes with irregular corneal surface and conjunctival congestion. The uncorrected visual acuity was 6/9, N6 (OU) by Snellen's chart, and anterior segment findings suggestive of dry eyes (OU) with reduced tear film breakup time. Schirmer test was 09 mm in both eyes after 5 min. The scalp hair was scanty, thin, and fragile [Figure 1a-c]. On further fundus examination, distinctive chorioretinal atrophic lesions were found (OU) in the periphery with normal disc appearance [Figures 2a and b, 3]. The skin around the face was thin and dry, with sparse eyelashes and brows. The child had delayed dentition associated with a few distorted teeth. He was born out of a non-consanguineous marriage with no developmental delays. The family history showed

This is an open-access article distributed under the terms of the Creative Commons Attribution-Non Commercial-Share Alike 4.0 License, which allows others to remix, transform, and build upon the work non-commercially, as long as the author is credited and the new creations are licensed under the identical terms.

©2024 Published by Scientific Scholar on behalf of Journal of Ophthalmic Research and Practice

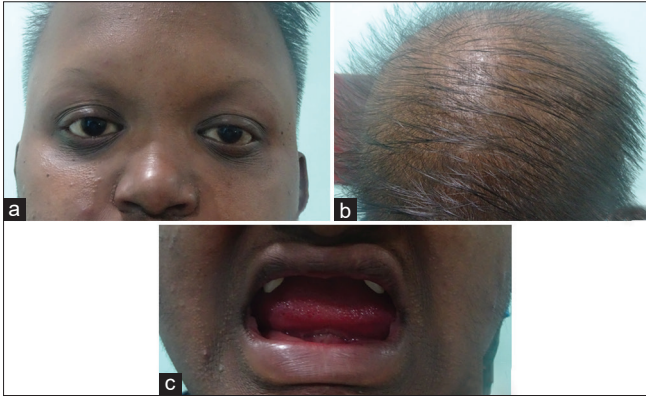

Figure 1: (a-c) Typical features of X-linked hypohidrotic ectodermal dysplasia (HED) in the index patient. (a) Patient with features of HED (sparse eyelashes and eyebrows). (b) Patient with features of HED (dry, brittle, and sparse hair). (c) Patient with features of HED (hypodontia with wide-spaced pointed teeth).

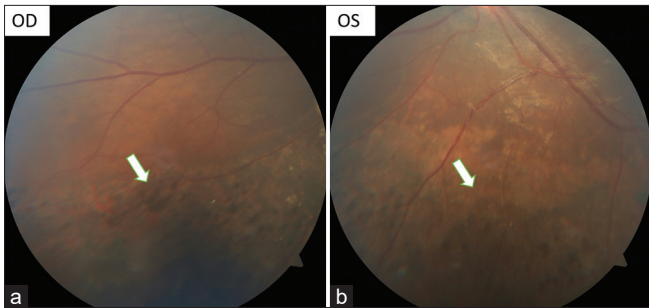


Figure 2: (a and b) Color fundus photograph (OU) shows multiple chorioretinal atrophic patches with hyperpigmentation (white arrow).

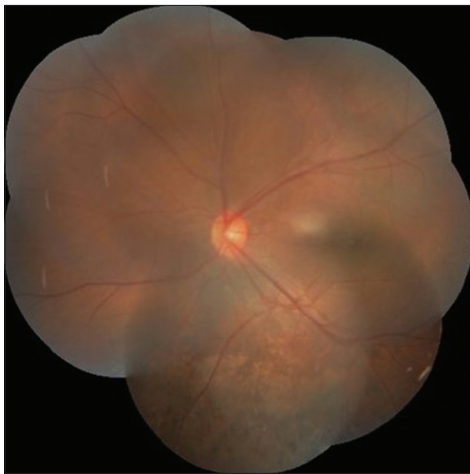

Figure 3: Montage photograph showing normal disc features along with chorioretinal lesion in periphery in the left eye (OS).

that the paternal grandaunt could not conceive as well as the paternal grandmother had only one child. Hence, we suspected the patient to have HED and went ahead with

molecular genetic testing to evaluate pathogenic variations. With pedigree chart mapping, the family members were also evaluated for any signs of HED and the presence of any variation. No other family member had a similar clinical picture.

The variant analysis done by Sanger sequencing was based on the EDA reference sequence ENST00000374552.9. The analysis uncovered X-linked recessive inheritance and the presence of a hemizygous missense variation in the index patient, located in exon 2 of the EDA gene (chrX: g.69957097G>A; c.467G>A) that resulted in the amino acid substitution of Histidine for Arginine at codon 156 (p.Arg156His), which was detected by NGS and this was, further, validated by Sanger sequencing.

The same pathogenic variation was, moreover, identified in the heterozygous condition in the asymptomatic sister of the index patient, indicating that the sister is an asymptomatic heterozygous carrier of this variant.

The patient needed a multimodal approach in terms of treatment. The patient was treated symptomatically for dry eye along with follow-up for chorioretinal lesion and advised to visit a physician, dentist, and ENT specialist for further evaluation.

DISCUSSION

The EDA is a type-II transmembrane protein with three important regions – (i) cysteine-rich C-Terminal tumor necrosis factor homology domain; (ii) collagen domain comprising 19 Gly-X₁Y repeats and a gap of two amino acids between repeat 11 and 12; and (iii) large extracellular domain which contains consensus furin protease recognition sequence.^[2] The most frequent mutation type reported is the missense/non-sense.^[3]

The missense variation detected in this case has been previously reported in patients affected with HED-1^[4], and functional studies of the R156H variant have shown that it impaired the cleavage of furin and, thus, sweat production.^[5] The missense variation identified in our study followed the tenets of the American College of Medical Genetics guidelines.^[6]

When the mother is a carrier, the chances of EDA mutation to be transmitted in each pregnancy are 50%, with male siblings being affected while the female siblings are carriers and may show minimal manifestations^[1], and this was confirmed in our study as well.

The affected hemizygous males have been reported to be the most severely impacted in terms of showing the classical signs, while the heterozygous female carriers have been reported to show differential expressivity in their phenotypes from being asymptomatic to showing only moderately affected clinical

features, such as defective dentition distribution as well as uneven distribution of sweating.^[7]

Therefore, genetic counseling is very much required in such cases as it helps in ruling out the probability of affected offspring from the affected individual.

CONCLUSION

The application of unbiased genetic testing in our study revealed variable expression of XLHED among the affected index patient and his asymptomatic sibling sister. Therefore, identification of the pathogenic variant of EDA through molecular genetic testing has several clinical benefits in diagnosis, counseling as well as prognosis for normal growth and development.

Ethical approval

The Institutional Review Board approval is not required.

Declaration of patient consent

The authors certify that they have obtained all appropriate patient consent.

Financial support and sponsorship

Nil.

Conflicts of interest

Dr. Nilutparna Deori and Dr. Dipankar Das are on the editorial board of the Journal.

Use of artificial intelligence (AI)-assisted technology for manuscript preparation

The authors confirm that there was no use of artificial intelligence (AI)-assisted technology for assisting in the

writing or editing of the manuscript and no images were manipulated using AI.

REFERENCES

1. Deshmukh S, Prashanth S. Ectodermal dysplasia: A genetic review. *Int J Clin Pediatr Dent* 2012;5:197-202.
2. Alksere B, Kornejeva L, Grinfelde I, Dzalbs A, Enkure D, Conka U, *et al.* A novel EDA variant causing X-linked hypohidrotic ectodermal dysplasia: Case report. *Mol Genet Metab Rep* 2021;29:100796.
3. Tumminello M, Gangemi A, Matina F, Guardino M, Giuffrè BL, Corsello G. First report of X-linked hypohidrotic ectodermal dysplasia with a hemizygous c.1142G > C in the EDA gene: Variant of uncertain significance or new pathogenic variant. *Ital J Pediatr* 2021;47:128.
4. Schneider P, Street SL, Gaide O, Hertig S, Tardivel A, Tschopp J, *et al.* Mutations leading to X-linked hypohidrotic ectodermal dysplasia affect three major functional domains in the tumor necrosis factor family member ectodysplasin-A. *J Biol Chem* 2001;276:18819-27.
5. Schneider H, Hammersen J, Preisler-Adams S, Huttner K, Rascher W, Bohring A. Sweating ability and genotype in individuals with X-linked hypohidrotic ectodermal dysplasia. *J Med Genet* 2011;48:426-32.
6. Richards S, Aziz N, Bale S, Bick D, Das S, Gastier-Foster J, *et al.* Standards and guidelines for the interpretation of sequence variants: A joint consensus recommendation of the American College of Medical Genetics and Genomics and the Association for Molecular Pathology. *Genet Med* 2015;17:405-24.
7. Modi BP, Del Bel KL, Lin S, Sharma M, Richmond PA, van Karnebeek CD, *et al.* Exome sequencing enables diagnosis of X-linked hypohidrotic ectodermal dysplasia in patient with eosinophilic esophagitis and severe atopy. *Allergy Asthma Clin Immunol* 2021;17:9.

How to cite this article: Deori N, Mahapatra M, Das D, Choudhury M, A rare case of X-linked hypohidrotic ectodermal dysplasia with chorioretinal lesions by missense mutation in ectodysplasin A gene from Northeast India. *J Ophthalmic Res Pract.* 2024;2:63-5. doi: 10.25259/JORP_22_2024