

Photo Essay *Comprehensive Ophthalmology*

## Management of an intralenticular foreign body

Asmita Mahajan<sup>1</sup>, K. S. Muhammed Nihal<sup>1</sup>

<sup>1</sup>Department of Ophthalmology, All India Institute of Medical Sciences, New Delhi, India.



**\*Corresponding author:**

Asmita Mahajan,  
Department of Ophthalmology,  
All India Institute of Medical  
Sciences, New Delhi, India.

asmitamahajn@gmail.com

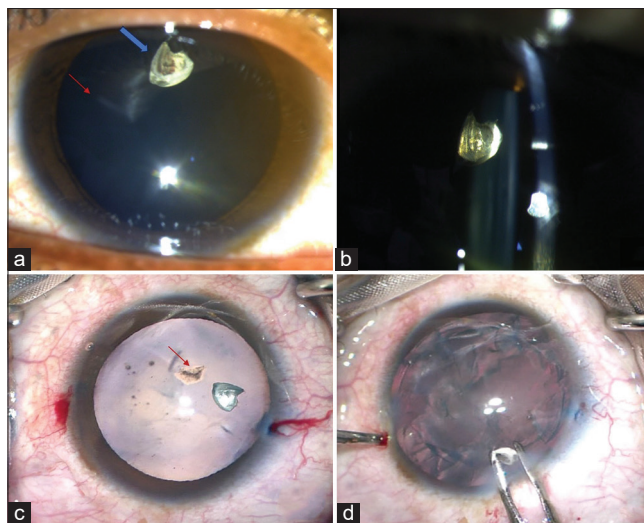
Received: 25 April 2024  
Accepted: 15 June 2024  
EPub Ahead of Print: 31 July 2024  
Published:

DOI  
10.25259/JORP\_14\_2024

Quick Response Code:



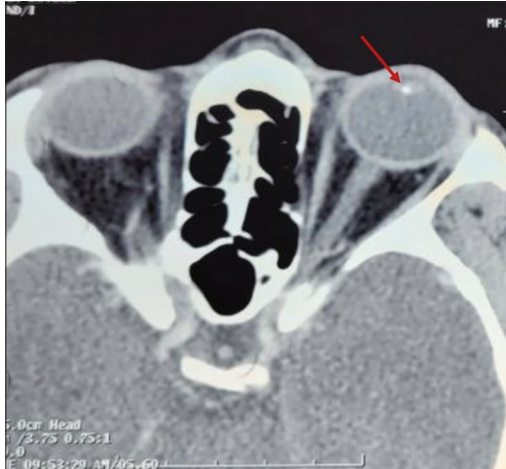
A 40-year-old mason worker reported to our clinic with a history of injury to the left eye while hammering a nail about one month ago. On examination, the visual acuity was 20/20. There was no conjunctival congestion or anterior chamber reaction. A linear corneal penetrating wound, self-sealed (Seidel's negative), was present. There was an irregular foreign body embedded in the lens [Figure 1a and b]. The posterior capsule appeared uninjured. The retinal evaluation by indirect ophthalmoscope was unremarkable. A computed tomography scan showed a well-defined hyperdense foreign body in the lens, suggesting its metallic nature. The patient was hailing from far and wanted surgical removal to avoid follow-up visits. Hence, we planned phacoemulsification of the lens and foreign body extraction with vitrectomy backup in place in anticipation of any posterior capsular weakness. Intraoperatively, after trypan blue staining, an



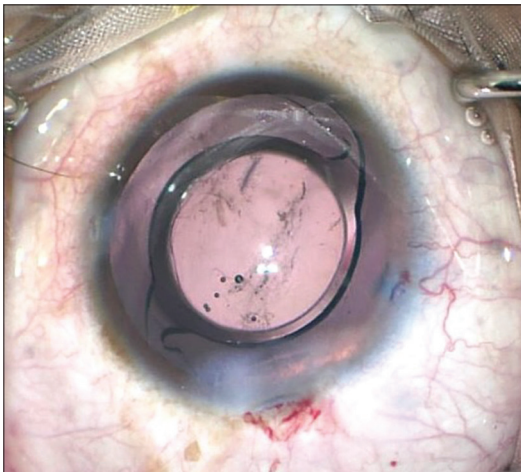
**Figure 1:** (a) Slit-lamp diffuse illumination image of the patient's eye showing linear corneal scar of entry wound (red arrow) with an irregular foreign body embedded in the lens (blue arrow), (b) slit-lamp focal illumination/optical section image showing a foreign body embedded deep into the lens matter. Posterior capsule appears intact, (c) intraoperative image after trypan blue staining showing anterior capsular rupture tear (red arrow), and (d) viscoelastic and Kelman McPherson forceps assisted removal of the foreign body after nuclear matter emulsification.

This is an open-access article distributed under the terms of the Creative Commons Attribution-Non Commercial-Share Alike 4.0 License, which allows others to remix, transform, and build upon the work non-commercially, as long as the author is credited and the new creations are licensed under the identical terms.

©2024 Published by Scientific Scholar on behalf of Journal of Ophthalmic Research and Practice



**Figure 2:** A computed tomography scan (axial section) of the orbit shows a hyperdense foreign body embedded in the lens matter (red arrow).



**Figure 3:** Intraoperative image with intraocular lens *in situ*.

anterior capsular tear was evident, which was included in the capsulorhexis [Figure 1c]. After nuclear matter removal using phacoemulsification, viscoelastic was used to maneuver the foreign body to the entry wound and McPherson forceps were used for its extraction [Figure 1d]. The CT scan image of the foreign body has been provided for reference in Figure 2. Subsequently, a hydrophobic intraocular lens was implanted in the bag [Figure 3]. Postoperatively, the patient had visual acuity of 20/20 on post-operative day one. Topical steroids were given to prevent any post-operative inflammation.

Intralenticular foreign bodies (ILFB) constitute 5–10% of all intraocular foreign bodies (IOFBs).<sup>[1]</sup> The metallic ILFB's may remain inert for long periods or be complicated by cataract,

uveitis, glaucoma, and siderosis bulbi.<sup>[2]</sup> If damage to the lens is localized, the visual axis is uninvolved, and the nature of the foreign body is nonmagnetic and inert, we can observe, and the foreign body may be left *in situ*. There are reports of focal lens opacities caused by minute, embedded foreign bodies where patients can maintain good visual function. If the foreign body is medium or large in size and metallic in nature, it warrants removal as the risk of complication is higher.<sup>[3]</sup>

Arora *et al.* have suggested the use of McPherson forceps (intraocular lens holding forceps) as an efficient alternative to a magnet for the removal of metallic foreign bodies.<sup>[4]</sup>

### Ethical approval

The Institutional Review Board approval is not required.

### Declaration of patient consent

The authors certify that they have obtained all appropriate patient consent.

### Financial support and sponsorship

Nil.

### Conflicts of interest

There are no conflicts of interest.

### Use of artificial intelligence (AI)-assisted technology for manuscript preparation

The authors confirm that there was no use of artificial intelligence (AI)-assisted technology for assisting in the writing or editing of the manuscript and no images were manipulated using AI.

### REFERENCES

1. Coleman DJ, Lucas BC, Rondeau MJ, Chang S. Management of intraocular foreign bodies. *Ophthalmology* 1987;94:1647-53.
2. Lee LR, Briner AM. Intralenticular metallic foreign body. *Aust N Z J Ophthalmol* 1996;24:361-3.
3. Pieramici DJ, Capone A Jr, Rubsamens PE, Roseman RL. Lens preservation after intraocular foreign body injuries. *Ophthalmology* 1996;103:1563-7.
4. Arora R, Sanga L, Kumar M, Taneja M. Intralenticular foreign bodies: Report of eight cases and review of management. *Indian J Ophthalmol* 2000;48:119-22.

**How to cite this article:** Mahajan A, Muhammed Nihal KS. Management of an intralenticular foreign body. *J Ophthalmic Res Pract*. doi: 10.25259/JORP\_14\_2024