



Invited Review Retina & Uvea

Retinal vasculitis – Current approach to diagnosis, investigations, and management

Jyotirmay Biswas¹, Namitha Rachel Mathew²

Departments of ¹Uvea and Ocular Pathology, ²Uvea and Medical Retina, Sankara Nethralaya, Chennai, Tamil Nadu, India.



***Corresponding author:**
Jyotirmay Biswas,
Department of Uvea and
Ocular Pathology, Sankara
Nethralaya, Chennai,
Tamil Nadu, India.

drjb@snmail.org

Received: 19 September 2024
Accepted: 30 September 2024
EPub Ahead of Print: 23 November 2024
Published: 21 December 2024

DOI
10.25259/JORP_34_2024

Quick Response Code:



ABSTRACT

Retinal vasculitis is defined as the inflammation of the retinal vessel wall, which may involve the veins (periphlebitis), arteries (periarteritis), capillaries (capillaritis), or a combination of these. It is an uncommon sight-threatening retinal vascular inflammatory disorder resulting in a plethora of clinical features. It may be associated with systemic inflammatory conditions, infections, neoplastic diseases, or may be idiopathic. Reaching a diagnostic etiology for retinal vasculitis is often a diagnostic challenge. Meticulous examination, essential laboratory investigations, fundus photography, autofluorescence, fundus fluorescein angiography, indocyanine green angiography, optical coherence tomography (OCT), OCT angiography, B scan ultrasonography, and widefield fundus imaging enable us to arrive at a diagnosis. Antivascular endothelial growth factor and laser photocoagulation help to arrest neovascularization. Newer agents, such as immunomodulators and biologics, are effective against these sight-threatening conditions. Early management often helps to salvage vision and minimize comorbidities in these conditions. This review highlights on diagnosis and management of retinal vasculitis.

Keywords: Eales' disease, Behcet's disease, Sarcoidosis, Systemic lupus erythematosus, Fundus fluorescein angiogram, Immunomodulatory agents

INTRODUCTION

Retinal vasculitis is defined as the inflammation of the retinal vessel wall, which may involve the veins (periphlebitis), arteries (periarteritis), capillaries (capillaritis), or a combination of these. It is an uncommon sight-threatening retinal vascular inflammatory disorder resulting in a variety of clinical manifestations. It affects about 3% of patients with uveitis. The estimated incidence is between 1 and 2/100,000, with the possibility of associated systemic disease.

Retinal vasculitis could be a presenting feature of various infectious, non-infectious, masquerade, systemic autoimmune, or isolated ocular disorders.

PATHOGENESIS OF RETINAL VASCULITIS

The outer blood-retinal barrier is formed by retinal pigment epithelium, which regulates the passage of nutrients from the choroid to the sub-retinal space. The endothelial lining of retinal vessels forms the inner blood-retinal barrier.^[1] The definite mechanisms of development are incompletely understood. It is presumed to be a type 3 hypersensitivity (immune complex-mediated) reaction, though cell-mediated and humoral immunity may have a role.^[2,3] Some studies have reported a

This is an open-access article distributed under the terms of the Creative Commons Attribution-Non Commercial-Share Alike 4.0 License, which allows others to remix, transform, and build upon the work non-commercially, as long as the author is credited and the new creations are licensed under the identical terms.

©2024 Published by Scientific Scholar on behalf of Journal of Ophthalmic Research and Practice

genetic predisposition with retinal vasculitis.^[4] There may be specific associations of some mutations with certain diseases, such as tumor necrosis factor (TNF) alpha-induced protein 3 in Behcet's-like disease and three prime repair exonuclease 1 in systemic lupus erythematosus (SLE).^[5,6]

CAUSES OF RETINAL VASCULITIS

Non-infectious causes include sarcoidosis, Behcet's disease, SLE, rheumatoid arthritis, multiple sclerosis (MS), and seronegative arthritis. Some of the infectious associations include syphilis, tuberculosis (TB), cat-scratch fever, Lyme's disease, and brucellosis.

Retinal vasculitis affecting the veins (periphlebitis) is commonly caused by, but not limited to sarcoidosis, Behcet's disease, TB, MS, pars planitis, human immunodeficiency virus, and birdshot chorioretinopathy. Retinal vasculitis affecting mainly the arteries (periarteritis) may be caused by SLE, polyarteritis nodosa (PAN), acute retinal necrosis (ARN), syphilis, idiopathic retinal vasculitis, aneurysms and neuroretinitis, and idiopathic retinal vasculitis.^[7]

Systemic evaluation is the main standpoint of diagnosis of primary retinal vasculitis. This requires extensive diagnostic tests to determine the systemic cause of retinal vasculitis. The diagnostic workup involves two parts as follows:

- Basic workup
- Laboratory tests are tailored according to the suspected etiology.

Periphlebitis is much more common than periarteritis. In India, the most common cause of retinal vasculitis is Eales' disease.^[8]

CLINICAL APPROACH TO A CASE OF RETINAL VASCULITIS

After a complete examination of the patient, it needs to be ascertained whether it is a case of retinal vasculitis alone or if it is associated with systemic disease, either autoimmune or infective.

EALES' DISEASE

Eales' disease is primarily a retinal perivasculitis. It affects healthy young adults, usually 15–40 years of age, predominantly males. It is commonly seen in the Indian subcontinent (1 in 135 ophthalmic patients at our center).

The disease has a characteristic natural course. It begins with peripheral retinal perivasculitis (inflammatory stage), followed by sclerosis of retinal veins (ischemic stage) and eventually neovascularization of the retina and/or optic disc, recurrent vitreous hemorrhage with or without retinal detachment (proliferative stage)^[9] [Figure 1a and b].

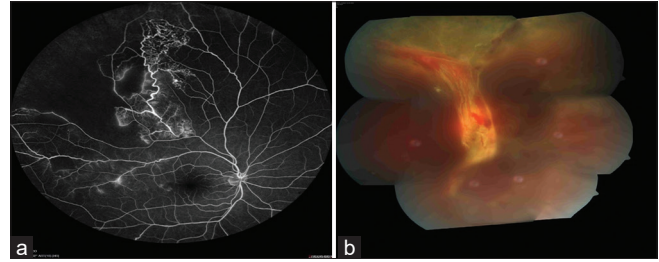


Figure 1: (a) Fundus fluorescein angiogram of a case of Eales' disease showing capillary non-perfusion. (b) Montage fundus photograph showing fibrovascular proliferation arising from optic disc in Eales' disease.

Presentation of Eales' disease

Anterior uveitis is uncommon, though, in the severe active periphlebitis, spillover non-granulomatous anterior uveitis may be present. Fundus findings consist of active perivasculitis with exudates around the retinal veins and superficial retinal hemorrhages involving one or more quadrants.

Eales' disease must be differentiated from branch retinal vein occlusion (BRVO). In BRVO, hemorrhages are confined to the affected quadrant, whereas in Eales' disease, patches of active or healed perivasculitis could be present in other quadrants as well. We have also seen an unusual presentation of papillophlebitis as an initial manifestation of Eales' disease.^[10]

Our hospital has done extensive research on Eales' disease. A total of 1005 patients with active pulmonary and 108 extrapulmonary TB cases at the Institute of TB and Chest Disease underwent complete ophthalmic examination. It was seen that none of these patients with active TB had Eales' disease.^[11]

In another study, high-resolution computed tomography chest confirmed that 51% of Eales' disease patients had pulmonary TB, compared to only 13.7% on chest X-ray.^[12]

Using nested and real-time polymerase chain reaction (PCR) of an enucleated specimen with Eales' disease and correlating with histology and immunohistochemical studies, it was found to be associated with *Mycobacterium tuberculosis* (MTb) deoxyribonucleic acid (DNA). CD8+ T cells were predominant.^[13]

MTb complex DNA has been detected in vitreous samples of Eales' disease. Five out of 12 samples were positive for MTb DNA, 1 out of 45 controls were positive, and none of them were culture-positive.^[14]

Fundus fluorescein angiography (FFA) is helpful in locating areas of capillary non-perfusion, any neovascularization, or doubtful macular edema. Ultra-widefield images (Optos) help to detect significantly more cases of active vasculitis

compared to clinical examination, while wide-field FFA is superior to Optos.^[15]

A swept source optical coherence tomography (OCT) study was done to analyze macular changes in Eales' disease. Out of a total of 38 eyes, 24 (63.15%) had macular changes. This included epiretinal membrane (ERM) in 18 (47.36%), cystoid macular edema (CME) in 3 (7.89%), foveal thinning in 3 (7.89%), ellipsoid zone thinning in 3 (7.89%), and vitreomacular traction in 1 (2.63%) patient.

We followed up 898 eyes of 500 patients for a period of 10–25 years (average 15.8 years). Some of the major findings were that Eales' disease was bilateral in 81% of the patients. Treatment with oral steroids in the acute stage and laser photocoagulation in the proliferative stage had a better prognosis. Recurrences are common – 52% had more than 5 recurrences in 10 years.^[16] We also found a rare association of neurological disease in three young males with Eales' disease who had generalized seizures and MRI showed ischemic infarction in the brain.^[17]

Eales' disease should be considered as tubercular retinal vasculitis based on the current molecular biologic studies.^[18] There are several questions about Eales' disease which remain unanswered. Relative less occurrence in females, its presentation in four stages, its involvement exclusively in the eyes, and the etiology of PCR-negative cases are still unclear.

Some retinal vasculitis entities that mimic Eales' disease include Behcet's disease, sarcoidosis, and SLE. They are discussed below-

Behcet's disease

Behcet's disease is a chronic, multisystem inflammatory disorder of unknown etiology, characterized by the triad of recurrent oral and genital ulcers, ocular lesions, and skin lesions.^[19] The disease occurs globally and has a strong association with human leukocyte antigens (HLAs) B5 and HLA B51.^[20]

Ophthalmic manifestations include a chronic relapsing bilateral non-granulomatous panuveitis, sometimes with a hypopyon, and retinal vasculitis. A critical element of Behcet's uveitis is occlusive necrotizing vasculitis. Periphlebitis appears as perivascular whitish haziness, often associated with periarteriolitis. It may be followed by bilateral branch retinal vessel occlusion^[21] [Figure 2].

We have analyzed the clinical profile and management of 25 patients with Behcet's disease at our center and found that the addition of immunosuppressants/biologics to steroids resulted in better improvement in the final visual acuity as compared to steroids alone.^[22]

Sarcoidosis

Sarcoidosis is a multisystem disease which may affect any organ, with the lungs and intrathoracic lymph nodes (bilateral

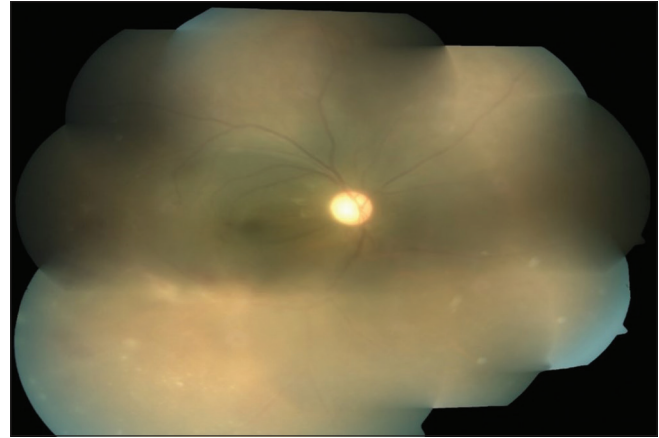


Figure 2: Montage fundus photograph showing active vasculitis and retinitis in Behcet's disease.

hilar lymphadenopathy) being the most frequently affected sites. Cutaneous manifestations, such as erythema nodosum, are the second most common manifestation. Sarcoidosis is diagnosed by the presence of non-caseating granuloma on histopathology, compatible clinical presentation, and exclusion of other causes of granulomatous inflammation.^[23]

Ocular sarcoidosis may affect the eye or its adnexa and may cause uveitis, eyelid abnormalities, episcleritis/scleritis, conjunctival granuloma, glaucoma, cataract, optic neuropathy, retinal vasculitis, lacrimal gland enlargement, and orbital inflammation. Ophthalmic manifestations may be isolated or be associated with systemic involvement.^[24] Retinal vasculitis in sarcoidosis typically presents with perivascular sheathing. "Candle-wax drippings" is the description given for scattered yellowish-white exudates along the retinal veins^[25] [Figure 3].

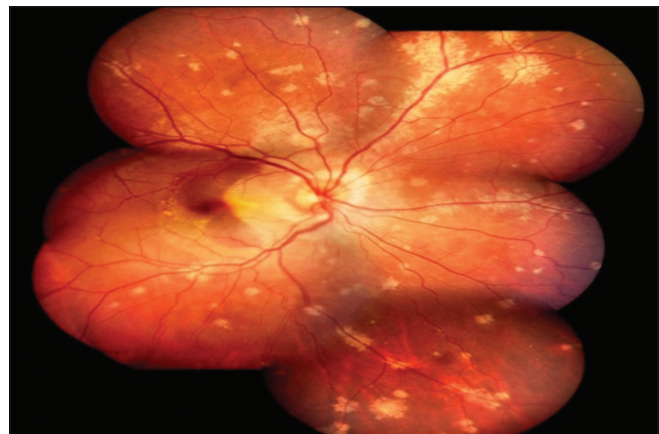


Figure 3: Montage fundus photograph showing multiple "Candlewax drippings" in ocular sarcoidosis

INFECTIVE RETINAL VASCULITIS

These include TB, cytomegalovirus retinitis, toxoplasmosis, syphilis, and ARN. In case of serpiginous choroiditis with retinal

vasculitis, always rule out tubercular etiology first. Ocular syphilis may rarely present as retinal vasculitis^[26] [Figure 4].

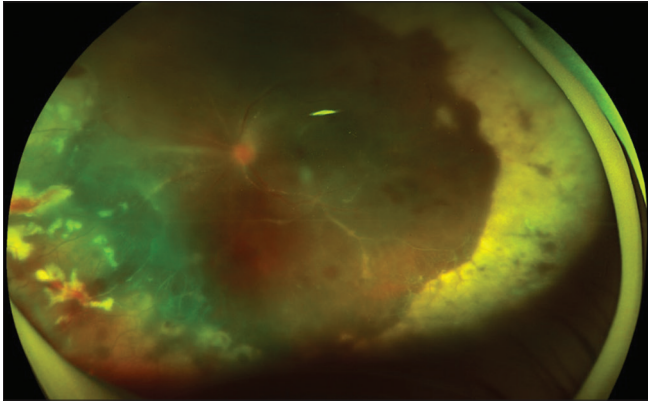


Figure 4: Acute retinal necrosis showing necrotizing retinitis and retinal vasculitis.

SYSTEMIC CONDITIONS ASSOCIATED WITH RETINAL VASCULITIS

These include mainly collagen vascular diseases such as SLE,^[27] granulomatosis with polyangiitis, and PAN. We also analyzed 20 cases of SLE retrospectively from a 15-year period and found that there was active vasculitis in 27% of cases and healed vasculitis in 23% of cases^[28] [Figure 5].

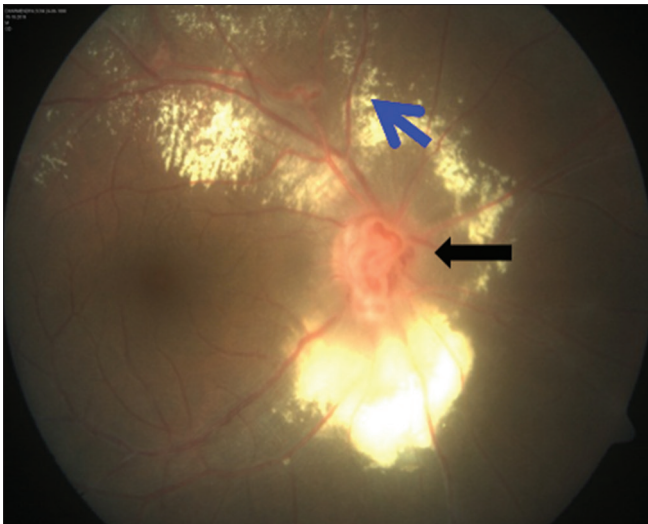


Figure 5: Fundus photograph showing aneurysm at the optic nerve head (black arrow) and along superior arcade (blue arrow) with surrounding exudates in a case of idiopathic retinal vasculitis, aneurysms, and neuroretinitis.

RETINAL VASCULITIS WITH NEUROLOGIC DISEASE

Occlusive retinal vasculitis is a rare manifestation in patients with MS, which may be complicated by neovascularization, vitreous hemorrhage, neovascular glaucoma, and retinal

detachment; therefore, MS needs to be ruled out in cases of ischemic retinal disease.^[29]

Systemic or ocular malignancy, such as primary vitreoretinal lymphoma and chronic myeloid leukemia may also present as retinal vasculitis.^[30]

INVESTIGATIONS

Important laboratory tests include:

- Complete blood count with differential.
- Erythrocyte sedimentation rate.
- C-reactive protein.
- Serum chemistry panel with tests for renal and liver functions.
- Blood sugar.
- Urinalysis.
- Venereal disease research laboratory (VDRL) test.
- Fluorescent treponemal antibody absorption (FTA-ABS) test.
- Tuberculin skin testing.
- Interferon- γ release assays for tuberculosis.
- Toxoplasmosis serology.
- Lyme disease serology.
- Dengue virus serology.
- Cat scratch disease serology.
- Rickettsial serology.
- Human immunodeficiency virus.
- Human T cell.
- Lymphoma virus type 1.
- Cytomegalovirus.
- Herpes simplex virus.
- Varicella zoster virus.
- Hepatitis virus and West Nile virus serology.
- Polymerase chain reaction to identify pathogens in ocular specimens.
- Serum angiotensin-converting enzyme.
- Rheumatoid factor.
- Antinuclear antibody.
- Anti-dsDNA.
- Antineutrophil cytoplasmic antibody.
- Antiphospholipid antibodies (lupus anticoagulants and anticardiolipin antibodies).
- Serum complement.
- CH50.
- AH50.
- Extractable nuclear antigen.
- Serum protein electrophoresis.
- Serum cryoglobulins.
- Human leukocyte antigen testing.
- Vitreous biopsy.
- Cerebrospinal fluid cytology.
- Cell count.

It is essential to follow a patient-tailored and step-wise approach to find the etiology and avoid unnecessary investigations.

MANAGEMENT APPROACH IN RETINAL VASCULITIS

It depends on the etiology. In general, if an infective etiology is found, it should be treated first. If non-infective, then systemic steroids are the mainstay of treatment. This includes oral prednisolone, periocular, or intravitreal triamcinolone injections. When inflammation is severe, intravitreal steroid implants can play a pivotal role, especially when systemic steroids are poorly tolerated, or there is associated macular edema. If the patient is unresponsive to steroids or has developed side effects, then immunosuppressive agents are added.

The commonly used steroid-sparing agents include cyclosporine, azathioprine, cyclophosphamide, methotrexate, and mycophenolate mofetil. The use of cyclophosphamide has reduced off late due to several associated dangerous side effects that include bone marrow suppression, hemorrhagic cystitis, infertility, alopecia, and possibly cancer.^[31] These agents can also be used in combination with each other or with steroids.

Biological agents have been developed to treat many immune-mediated conditions. These drugs may outperform traditional immunosuppressive medications with regard to their anti-inflammatory potential. Biologics include interferon alpha, anti-TNF alpha agents like infliximab, monoclonal immunoglobulin G1 antibody – Adalimumab, anti-interleukin-6 receptor antibody – Tocilizumab, anti-CD20 antibody, Rituximab, etc [Figure 6a and b].^[32-34]

MANAGEMENT OF EALES' DISEASE

- Inflammatory stage: Treat with corticosteroid and antitubercular therapy
- Neovascularization: Laser photocoagulation

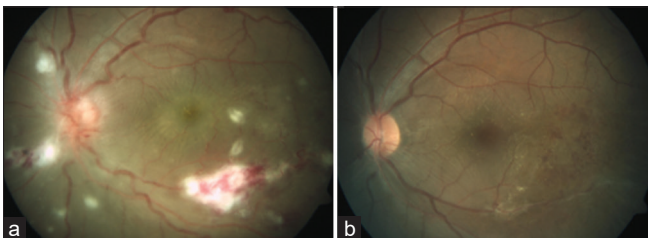

Figure 6: (a) This 21-year-old male patient with active retinal vasculitis was Mantoux positive, QuantiFERON tuberculosis gold positive with high resolution computed tomography chest showing features of pulmonary tuberculosis. (b) Resolution of retinal vasculitis after treatment with antitubercular therapy and steroid.

- Vitreous hemorrhage, tractional retinal detachment: Vitrectomy ± endolaser.^[9]

In Behcet's disease, immunosuppressive agents are the first choice. Cyclosporine is the most commonly used drug.^[34] Immunosuppressives or biologicals are beneficial in Behcet's disease and SLE.^[35]

CONCLUSION

Retinal vasculitis can be associated with various ocular and systemic diseases. Eales' disease is a T-cell-mediated immunologic reaction to mycobacterial TB DNA in genetically predisposed patients. Ultrawide-field imaging is beneficial to document peripheral vascular changes in Eales' disease. Frosted branch angiitis is a sign, not a separate disease. Management depends on the etiology of retinal vasculitis. Systemic steroids work in the majority of cases.

Ethical approval

The Institutional Review Board approval is not required.

Declaration of patient consent

Patient's consent not required as patients identity is not disclosed or compromised.

Financial support and sponsorship

Nil.

Conflicts of interest

Dr. Jyotirmay Biswas is on the editorial board of the Journal.

Use of artificial intelligence (AI)-assisted technology for manuscript preparation

The authors confirm that there was no use of artificial intelligence (AI)-assisted technology for assisting in the writing or editing of the manuscript and no images were manipulated using AI.

REFERENCES

1. Campbell M, Humphries P. The blood-retina barrier: Tight junctions and barrier modulation. *Adv Exp Med Biol* 2012;763:70-84.
2. Boonsopon S, Anesi S. Retinal vasculitis: Fundamentals, diagnostics, and management. *Siriraj Med J* 2021;73:493-500.
3. Levy-Clarke GA, Nussenblatt R. Retinal vasculitis. *Int Ophthalmol Clin* 2005;45:99-113.
4. Bassuk AG, Yeh S, Wu S, Martin DF, Tsang SH, Gakhar L, *et al.* Structural modeling of a novel CAPN5 mutation that causes uveitis and neovascular retinal detachment. *PLoS One*

- 2015;10:e0122352.
5. Zhou Q, Wang H, Schwartz DM, Stoffels M, Park YH, Zhang Y, *et al.* Loss-of-function mutations in TNFAIP3 leading to A20 haploinsufficiency cause an early-onset auto-inflammatory disease. *Nat Genet* 2016;48:67-73.
 6. Lee-Kirsch MA, Gong M, Chowdhury D, Senenko L, Engel K, Lee YA, *et al.* Mutations in the gene encoding the 3'-5' DNA exonuclease TREX1 are associated with systemic lupus erythematosus. *Nat Genet* 2007;39:1065-7.
 7. Biswas J, Bagrecha N, Maitra P. Retinal vasculitis: An update with our experience. *TNOA J Ophthalmic Sci Res* 2021;59:137-47.
 8. Das T, Biswas J, Kumar A, Nagpal PN, Namperumalsamy P, Patnaik B, *et al.* Eales' disease. *Indian J Ophthalmol* 1994;42:3-18.
 9. Biswas J, Sharma T, Gopal L, Madhavan HN, Sulochana KN, Ramakrishnan S. Eales disease--an update. *Surv Ophthalmol* 2002;47:197-214.
 10. Patel D, Majumder PD, Biswas J. Papillophlebitis as an initial presentation of Eales' disease. *Oman J Ophthalmol* 2020;13:161-3.
 11. Biswas J, Badrinath SS. Ocular morbidity in patients with active systemic tuberculosis. *Int Ophthalmol* 1995;19:293-8.
 12. Kharel Sitaula R, Iyer V, Noronha V, Dutta Majumder P, Biswas J. Role of high-resolution computerized tomography chest in identifying tubercular etiology in patients diagnosed as Eales' disease. *J Ophthalmic Inflamm Infect* 2017;7:4.
 13. Shah A, Giridhar S, Patnaik G, Mhatre R, Das D, Janani MK, *et al.* Histopathological, immunohistochemical and molecular biologic study of an enucleated specimen of a case of Eales' disease. *J Ophthalmic Inflamm Infect* 2021;11:29.
 14. Madhavan HN, Lily Therese K, Gunisha P, Jayanthi U, Biswas J. Polymerase chain reaction for detection of *Mycobacterium tuberculosis* in epiretinal membrane in Eales' disease. *Invest Ophthalmol Vis Sci* 2000;41:822-5.
 15. Agarwal AA, Sharma R, Biswas J. Role of ultra-widefield imaging in Eales' disease: A case series. *Ocul Immunol Inflamm* 2020;28:1187-91.
 16. Biswas J, Reesha KR, Pal B, Gondhale HP, Kharel Sitaula R. Long-term outcomes of a large cohort of patients with Eales' disease. *Ocul Immunol Inflamm* 2018;26:870-6.
 17. Biswas J, Raghavendran R, Pinakin G, Arjundas D. Presumed Eales' disease with neurologic involvement: Report of three cases. *Retina* 2001;21:141-5.
 18. Biswas J, Ravi RK, Naryanasamy A, Kulandai LT, Madhavan HN. Eales' disease - current concepts in diagnosis and management. *J Ophthalmic Inflamm Infect* 2013;3:11.
 19. Singal A, Chhabra N, Pandhi D, Rohatgi J. Behcet's disease in India: A dermatological perspective. *Indian J Dermatol Venereol Leprol* 2013;79:199-204.
 20. Ohno S, Ohguchi M, Hirose S, Matsuda S, Wakisaka A, Aizawa M. Close association of HLA B51 with Behcet's disease. *Arch Ophthalmol* 1982;100:1455-8.
 21. Tugal-Tutkun I, Gupta V, Cunningham ET. Differential diagnosis of Behcet Uveitis. *Ocul Immunol Inflamm* 2013;21:337-50.
 22. Ramdoss J, Singh P, Ahmed AS, Biswas J. Clinical profile and management with immunosuppressants and biologics in Behcet's uveitis: A cohort of 25 patients from a tertiary eye care center in South India. *Indian J Ophthalmol* 2023;71:1972-6.
 23. Ungprasert P, Ryu JH, Matteson EL. Clinical manifestations, diagnosis, and treatment of sarcoidosis. *Mayo Clin Proc Innov Qual Outcomes* 2019;3:358-75.
 24. Pasadhika S, Rosenbaum JT. Ocular sarcoidosis. *Clin Chest Med* 2015;36:669-83.
 25. Gould H, Kaufman HE. Sarcoid of the fundus. *Arch Ophthalmol* 1961;65:453-6.
 26. Dutta Majumder P, Chen EJ, Shah J, Ching Wen Ho D, Biswas J, See Yin L, *et al.* Ocular syphilis: An update. *Ocul Immunol Inflamm* 2019;27:117-25.
 27. Magesan K, Nangia P, Manoharan A, Sitaula RK, Srikantiah C, Biswas J. Systemic lupus erythematosus (SLE) associated uveitis in India - A case series. *Indian J Ophthalmol* 2024;72:677-80.
 28. Nangia PV, Viswanathan L, Kharel R, Biswas J. Retinal involvement in systemic lupus erythematosus. *Lupus Open Access* 2017;2:1000129.
 29. Khalil M, Buelens T, Borrelli S, Vanderhulst J, Willermain F, Makhoul D, *et al.* Multiple sclerosis and occlusive retinal vasculitis: A case series. *Acta Ophthalmol* 2022;100:S275.
 30. Sonne SJ, Shieh WS, Srivastava SK, Smith BT. Lymphoma masquerading as occlusive retinal vasculitis: A case study. *Am J Ophthalmol Case Rep* 2020;19:100777.
 31. Davatchi F, Sadeghi Abdollahi B, Shams H, Shahram F, Nadji A, Chams-Davatchi C, *et al.* Combination of pulse cyclophosphamide and azathioprine in ocular manifestations of Behcet's disease: Longitudinal study of up to 10 years. *Int J Rheum Dis* 2014;17:444-52.
 32. Becker MD, Heiligenhaus A, Hudde T, Storch-Hagenlocher B, Wildemann B, Barisani-Asenbauer T, *et al.* Interferon as a treatment for uveitis associated with multiple sclerosis. *Br J Ophthalmol* 2005;89:1254-7.
 33. Sharma PK, Markov GT, Bajwa A, Foster CS. Long-term efficacy of systemic infliximab in recalcitrant retinal vasculitis. *Retina* 2015;35:2641-6.
 34. Fabiani C, Vitale A, Emmi G, Vannozzi L, Lopalco G, Guerriero S, *et al.* Efficacy and safety of adalimumab in Behcet's disease-related uveitis: A multicenter retrospective observational study. *Clin Rheumatol* 2017;36:183-9.
 35. Sadhu S, Dutta Majumder P, Biswas J. Biological therapy in refractory cases of uveitis and scleritis: An analysis of 18 cases from a tertiary eye care center from South India. *Indian J Ophthalmol* 2020;68:1929-33.

How to cite this article: Biswas J, Mathew NR. Retinal vasculitis – Current approach to diagnosis, investigations, and management. *J Ophthalmic Res Pract.* 2024;2:47-52. doi: 10.25259/JORP_34_2024