



Case Report *Comprehensive Ophthalmology*

Suspected corneal metastasis in a case of nasopharyngeal carcinoma

Charu Arora¹, Dipankar Das²

Departments of ¹Glaucoma and ²Uveitis, Sri Sankaradeva Nethralaya, Guwahati, Assam, India.



***Corresponding author:**

Charu Arora,
Department of Glaucoma,
Sri Sankaradeva Nethralaya,
Guwahati, Assam, India.

charuarora1971@yahoo.co.in

Received: 04 July 2024
Accepted: 30 September 2024
Epub Ahead of Print: 18 November 2024
Published:

DOI
[10.25259/JORP_26_2024](https://doi.org/10.25259/JORP_26_2024)

Quick Response Code:



Supplementary File is available on:

https://doi.org/10.25259/JORP_26_2024

ABSTRACT

A 13-year-old girl child undergoing chemotherapy for the terminal stage of undifferentiated metastatic nasopharyngeal carcinoma presented to us with a complaint of poor vision in the left eye (LE). There were no complaints of pain, photophobia, or watering. On examination, there was asymmetric optic disc pallor in both eyes with a patch of corneal infiltration in the LE that was difficult to attribute to any obvious common pathology. The richly vascular posterior segment is a well-known target of ocular metastasis for several malignancies. Corneal involvement, if it occurs, is through local spread. However in this case, in the absence of any other factors to account for this corneal infiltration along with presence of adjacent corneal neovascularization, corneal metastasis is highly suspected. Unfortunately, histopathological evidence could not be collected due to the poor general health of the patient, who did not turn up for a follow-up.

Keywords: Corneal metastasis, Nasopharyngeal carcinoma, Anterior segment metastasis, Corneal infiltration

INTRODUCTION

Ocular metastasis of systemic malignancies is usually limited to heavily vascularized tissues. However, in the event of vascularization of the peripheral cornea, when new vessels can be seen advancing into corneal tissue, the possibility of corneal metastasis from a late-stage tumor cannot be completely denied.

CASE REPORT

A 13-year-old girl child in very poor general health from northeast India visited us with a chief complaint of blurring of vision in the left eye (LE) for the past 1 month. The patient was on chemotherapy (Gemcitabine + Cisplatin) for the past one year for undifferentiated, metastatic squamous cell nasopharyngeal carcinoma (NPC). A histopathology report from the referral center is submitted as a Supplementary File.

On examination, the best-corrected vision was 6/6 in the right eye and finger counting two meters in the LE. Intraocular pressure by Goldmann applanation tonometer was 10 and 6 mmHg in the right and LE, respectively.

External and slit-lamp examination (SLE) for the anterior segment was unremarkable in the right eye.

This is an open-access article distributed under the terms of the Creative Commons Attribution-Non Commercial-Share Alike 4.0 License, which allows others to remix, transform, and build upon the work non-commercially, as long as the author is credited and the new creations are licensed under the identical terms.

©2024 Published by Scientific Scholar on behalf of Journal of Ophthalmic Research and Practice

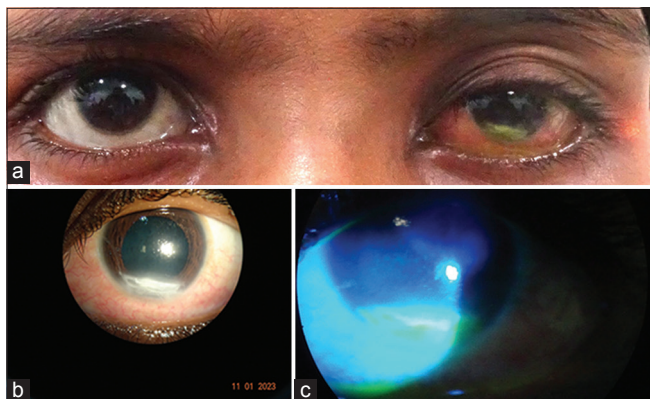


Figure 1: A 13-year-old girl with carcinoma nasopharynx (a) Front view showing left eye corneal infiltration with mild redness. (b) Slit-lamp picture of the cornea shows infiltration. (c) Fluorescein stain positive lesion.

In LE, there was diminished corneal sensation and partial ptosis but no lagophthalmos [Figure 1a]. SLE revealed a fluorescein stain-positive area of corneal infiltration from 5–7 o'clock with mild attendant corneal vascularization and conjunctival congestion [Figure 1b and c].

Fundus examination showed optic disc pallor in both eyes, more pronounced in LE [Figure 2].

Magnetic resonance imaging scan brain and orbit showed a large NPC with locoregional spread, including the spine and orbit [Figure 3].

The patient was prescribed topical broad-spectrum antibiotics and lubricants. She was advised anterior segment optical coherence tomography but was lost to follow-up.

DISCUSSION

NPC, a rare malignant tumor of the mucosal epithelial lining of the nasopharynx, is known to have high incidences in people from Southern China, whereas those from Southeast Asia, North Africa, and Innuits of Canada and Alaska have intermediate incidences.^[1]

Environmental factors such as consumption of preserved food, smoking, alcohol consumption, household air pollution, possible poor oral health, occupational exposure to formaldehyde and wood dust, presence of high levels of uranium in soil (some African countries), as well as Epstein bar virus infection along with mongoloid genes have been implicated in various studies.^[2] In India North Eastern states of Nagaland, Manipur and Mizoram show similar incidence rates as that of southern China, Kohima having the highest of 19.4/100,000 people.^[3]

The World Health Organization classification recognizes three subtypes of NPC. Type one is Keratinizing, type two is non-keratinizing, and type three is undifferentiated squamous cell carcinoma. Distant metastasis to bone,

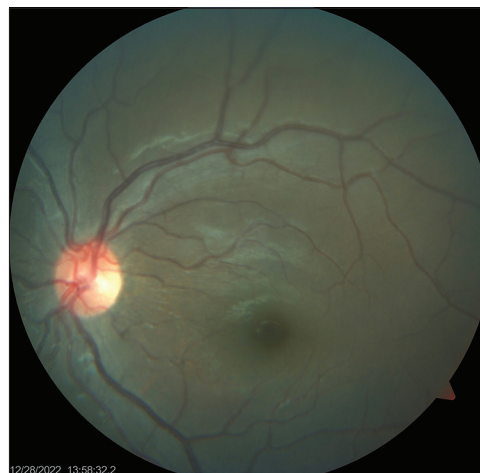

Figure 2: Left optic disc photograph showing temporal pallor.

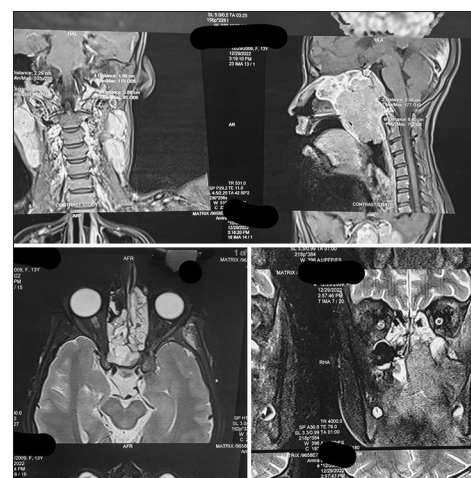


Figure 3: Collage of MRI Scans showing extent of locoregional spread of nasopharyngeal carcinoma.

lung, mediastinum, and liver can occur. Ophthalmology consult is usually due to orbital pain and blurred vision.^[4,5] Lagophthalmos can lead to corneal involvement. However, in the absence of lagophthalmos and corneal exposure, the presence of stain-positive corneal infiltration in our case is intriguing. Infective etiology seems unlikely in the absence of tell-tale signs of infection, such as pain or photophobia. A literature search for both antimetabolites did not yield any side effects leading to such corneal alterations. Therefore, these corneal changes are highly indicative of hitherto unreported metastasis of NPC to the cornea.

CONCLUSION

Metastasis to cornea is theoretically impossible, yet in this case, in the absence of lagophthalmos and any lid margin disease, the presence of corneal infiltration may suggest an unheard-of diagnosis of corneal metastasis. Corneal vascularization,

in this case might have facilitated the malignant cells to gain access to the corneal tissue. However, histopathology could have given us definite proof for the same, which, unfortunately, due to the moribund state of the patient, was not possible.

Ethical approval

The Institutional Review Board approval is not required.

Declaration of patient consent

The authors certify that they have obtained all appropriate patient consent.

Financial support and sponsorship

Nil.

Conflicts of interest

There are no conflicts of interest.

Use of artificial intelligence (AI)-assisted technology for manuscript preparation

The authors confirm that there was no use of artificial intelligence (AI)-assisted technology for assisting in the

writing or editing of the manuscript and no images were manipulated using AI.

REFERENCES

1. Sung H, Ferlay J, Siegel RL, Laversanne M, Soerjomataram I, Jemal A, *et al.* Global cancer statistics 2020: GLOBOCAN estimates of incidence and mortality worldwide for 36 cancers in 185 countries. *CA Cancer J Clin* 2021;71:209-49.
2. Beyene ET, Ketema SG, Alebachew AN, Saleh MY, Gebremariam TA. Descriptive epidemiology of nasopharyngeal carcinoma at Tikur Anbessa Hospital, Ethiopia. *BMC Cancer* 2021;21:540.
3. Katakaci AC, Simons MJ, Das AK, Sharma K, Mehra NK. Nasopharyngeal carcinoma in northeastern states of India. *Chin J Cancer* 2011;30:106-13.
4. Brennan B. Nasopharyngeal carcinoma. *Orphanet J Rare Dis* 2006;1:23.
5. Alrashed SH, Alkatan HM, Alarfaz M, Alnahdi MA, Almeshari NZ, Almutairi FZ, *et al.* Nasopharyngeal carcinoma (NPC) in the ophthalmic practice: A serious neoplasm presenting initially to ophthalmologists. *Saudi J Ophthalmol* 2021;35:225-9.

How to cite this article: Arora C, Das D. Suspected corneal metastasis in a case of nasopharyngeal carcinoma. *J Ophthalmic Res Pract.* doi: 10.25259/JORP_26_2024