

Case Report Oculoplasty

Benign fibrous histiocytoma of the lacrimal sac

Panshak Elisha Tenmang¹, Philip Ojile Akpa², Yisumwoni Kaigama¹, Simi Nehemiah Dung¹

Departments of ¹Ophthalmology, ²Anatomic pathology and Forensic Medicine, Jos University Teaching Hospital, Jos Plateau State, Nigeria.



***Corresponding author:**

Panshak Elisha Tenmang,
Department of Ophthalmology,
Jos University Teaching
Hospital, Jos Plateau State,
Nigeria.

panshak_tenmang@yahoo.com

Received: 01 June 2024
Accepted: 26 August 2024
Epub Ahead of Print: 16 October 2024
Published:

DOI
[10.25259/JORP_21_2024](https://doi.org/10.25259/JORP_21_2024)

Quick Response Code:



ABSTRACT

Benign fibrous histiocytoma (BFH) is a tumor of mesenchymal origin, mostly seen in subcutaneous tissues, and it commonly affects males with a mean age of 55 years. We report a 60-year-old with lacrimal sac swelling that was recurrent. Initially, it started as the size of a black-eyed bean seed, which gradually progressed to the size of a small-sized peewee egg. She had complete excision of the mass with no bony erosions or intracranial extension. Histopathology revealed a BFH of the lacrimal sac. She is currently doing well.

Keywords: Bening, Fibrous histiocytoma, Lacrimal sac

INTRODUCTION

Fibrous histiocytoma (FH) is a common primary benign tumor of mesenchymal origin. This benign tumor is often seen to appear in areas exposed to the sun, namely, skin, orbital tissues, lids, conjunctiva, and ocular are limbus.^[1,2] The presence of these subcutaneous tumors in deep soft tissues is rare.^[3] Most FH are benign; however, some are locally aggressive and malignant in nature.^[1,2] Unlike the cutaneous form, which is common, non-cutaneous benign FH (BFH) comprises 1% of all BFH lesions. This tumor is commonly seen in the middle-aged; mean age of presentation is 55 years, ranges from 1 to 71 years, commoner in males with a male-to-female ratio of 2.5:1.^[3-5]

A histiocyte or fibroblast is the probable site of origin. It possibly is a primitive mesenchymal cell which has diverge differentiation ability, and can express histiocytic, fibroblastic, and myofibroblastic phenotypes.^[1-6]

BFH frequently originates as a painless mass with non-specific symptoms which result from disruption of normal anatomy and physiology of the region of origin.^[7] These tumors are seen clinically to appear as slowly enlarging, well-circumscribed mass.^[8]

The treatment of this tumor typically involves a wide-margin surgical excision where the complete capsule is removed during excision to avoid recurrence.^[9] Other treatment modalities that have been tried on an individual basis are adjuvant radio or chemotherapy.^[10]

We report a 60-year-old female who came with a three-year history of painless left medial lower lid mass that was excised once, with associated recurrent mucoid discharge and tearing.

CASE REPORT

A 60-year-old Nigerian woman reported with a three-year history of gradual painless swelling involving with the medial aspect of the left lower lid, which was painless, initially small as the size of a black-eyed bean, but progressed slowly to the size of a small peewee egg to erode the overlying skin [Figure 1]. There was an associated history of discharge, tearing from the eye but no bleeding. There was reduced, vision in the left eye, no protrusion of the eye or abnormal deviation of the eye, no previous history of irradiation involving the face or any other part of the body, and no swelling involving other parts of the body. She had an attempted excision done by a traditionalist, and the swelling recurred three months later.

Pre-operative findings

Examination of the left eye revealed a vision of counting fingers at 4 m with a growth involving the medial aspect of the lower lid around the area of the lacrimal sac; it was covered by membrane and necrotic tissue. The growth measured about 1.5 cm in height and a width of 1 cm on its external surface. It was non-tender; however, a mucoïd discharge was noticed from the base of the mass whenever the mass was touched. The nostrils were clear, with no mass extending into the nose. There was no abnormality seen on the examination of the right eye.

Investigations

The patient had a computed tomography (CT)-scan done, which showed a large exophytic soft-tissue mass arising from the inferomedial pre-septal part of the left orbit. The lesion measured 44 mm × 22 mm × 26 mm and showed homogeneous post-contrast enhancement. There was no demonstrable infiltration of the globe or adjacent medial rectus muscle. The optic nerve, other rectus muscles, and intraocular structures were essentially normal. There was no bony erosion of the adjacent ethmoids, no intracranial extension, and paranasal sinuses were essentially normal. A radiological diagnosis of orbital lymphoma was made [Figure 2].

Intraoperative findings

Surgery was done under general anesthesia after obtaining informed consent from the patient and on the anesthetist's confirmation of the patient being fit to undergo the surgical procedure. A curvilinear incision was made 6 mm below the lower lid margin and extended medially and laterally over the cutaneous surface of the mass. A blunt dissection was made to access the lower border of the mass and all around the mass. It was then removed en block, revealing a well-circumscribed mass measuring 3.7 cm × 1.0 cm and a bare lacrimal fossa. Probing and syringing confirmed the absence of the lacrimal sac. Hemostasis was secured, exposing a dead space, which

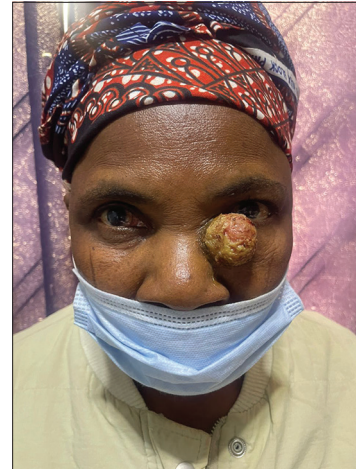


Figure 1: Left medial infraorbital mass around the lacrimal sac area with sloughing surface.

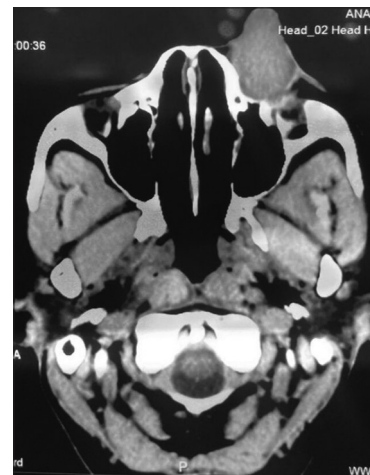


Figure 2: Axial computed tomography scan showing a large exophytic mass without bony erosion.

was closed by suturing in layers with Vicryl 5/0 absorbable suture, followed by firm pressure padding [Figure 3].

Pathology of the specimen

Gross findings

Excised mass was an encapsulated greyish brown soft to firm mass with a smooth external surface. It was roughly spherical and measured 3 cm in its long diameter and 2 cm in its shorter diameter. Serial cut sections showed a mostly greyish-white homogenous surface with dark brown spots [Figure 4].

Microscopy findings

Histologic sections of the lower lid mass showed a scanty eosinophilic hyaline stroma within which was seen

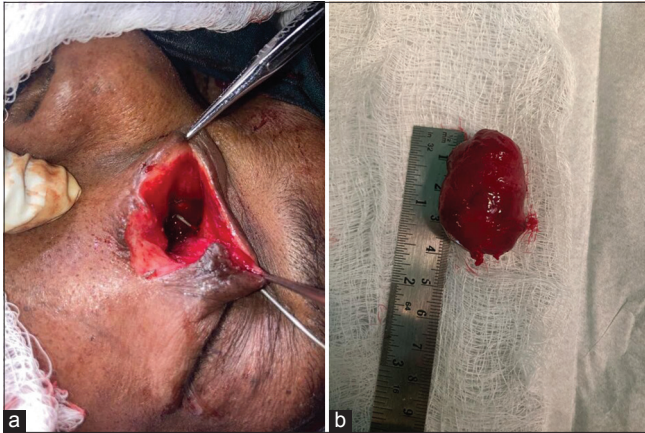


Figure 3: (a) A dead space seen following the removal of the mass with lacrimal probes exposed on passing them through the superior and inferior puncta. (b) A well-circumscribed encapsulated mass measuring 3.7 cm by 1 cm.

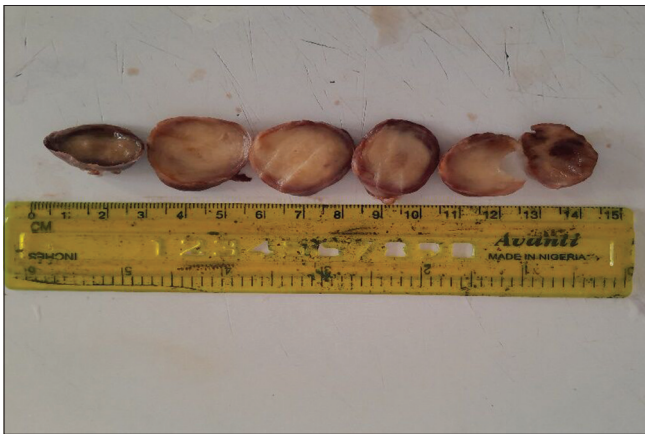

Figure 4: A resected lower lid mass with greyish-white cut surfaces.

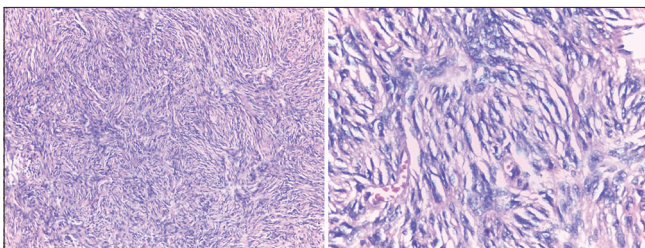


Figure 5: (a) Photomicrograph (hematoxylin and eosin) $\times 100$ magnification showing prominent storiform pattern of bland spindle cells. (b) ($\times 400$ magnification) showing bland spindle cells with vesicular nuclei in storiform pattern and multinucleate giant cells.

monomorphic spindle cells with ill-defined eosinophilic cytoplasm and elongated bland vesicular nuclei disposed in storiform pattern. Multinucleated giant cells, a few staghorn-like blood vessels, and scanty mitotic figures were also noted [Figure 5].

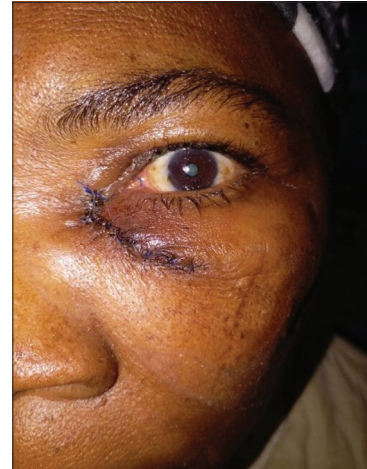

Figure 6: Wound at one week post-operative review.

Post-operative care

The pressure padding was left over the area for 72 hours, and the patient was placed on oral systemic analgesics (Diclofenac 50 mg twice daily for 5 days, oral systemic antibiotic (Augmentin 625 mg twice daily for 7 days), Vitamin C 200 mg 3 times daily for 7 days, and tabs Chymotrypsin 20,000 units orally 3 times daily. The pressure dressing was removed on the fourth day, and the patient was discharged home.

Post-operative follow-up

The patient was seen in the clinic at one week and four weeks after discharge. The wound edge was well apposed and healing well. She still had tearing from her left eye, and she has planned for left cataract extraction after three months of review [Figure 6].

DISCUSSION

BFH can be classified anatomically into cutaneous and deep forms. The deep FH is rare, accounting for about 1–2% of all BFH.

This is the first documentation of a BFH involving the eyelid and the lacrimal sac in our institution and the north-central part of Nigeria. Fibrous histiocytoma is a rare tumor whose ocular manifestations usually involve the orbit or, less commonly, the ciliary body and conjunctiva. The fibrous histiocytoma involving the lacrimal sac is rare, and very few cases have been reported globally.^[10] The tumor most commonly arises in the dermis but may also arise from parenchymal organs and soft tissues. The BFH is often seen to appear in areas exposed to sun, namely, skin and orbital tissues, while the presence of this tumor in the deeper soft tissue of the head and neck has been rarely reported.^[2] The

tumor has been reported to have a slight male predilection by some authors;^[2] however, we present this in a female.

Subcutaneous BFH is mostly painless masses that are nodular, with minimal mobility and firm to elastic in consistency, mostly without bony erosion. For BFH, mostly the skin overlying the lesion is normal with no lymphadenopathy. Clinically, the tumor appears as a soft-tissue lesion.^[3] Deep BFH commonly appears as a painless, slow-growing mass whose symptoms are manifested by the disruption of normal anatomy and physiology of the body part where the tumor originates.^[2]

Orbital radiological imaging such as CT, magnetic resonance imaging, and/or time-resolved contrast kinetics imaging has a significant role in the accurate diagnosis of this lesion; they usually reveal a well-circumscribed soft-tissue mass. It can resemble a cavernous hemangioma or a schwannoma. A biopsy with special immunohistochemistry staining is necessary to arrive at a definitive diagnosis.^[1]

The preferred management of benign fibrohistiocytoma is complete surgical excision of the mass with its capsule. The literature review has shown that incomplete excision is a cause of disease recurrence and can also cause malignant transformation. Advanced cases may require orbital exenteration or irradiation.^[1] The rate of recurrence has been reported to be up to 31%.

CONCLUSION

Benign FH involving the lacrimal sac is of rare occurrence. Imaging modalities and histopathology can clinch the diagnosis. Complete excision of the tumor, including its capsule, is the definitive treatment for this condition.

Ethical approval

The Institutional Review Board approval is not required.

Declaration of patient consent

The authors certify that they have obtained all appropriate patient consent.

Financial support and sponsorship

Nil.

Conflicts of interest

There are no conflicts of interest.

Use of artificial intelligence (AI)-assisted technology for manuscript preparation

The authors confirm that there was no use of artificial intelligence (AI)-assisted technology for assisting in the writing or editing of the manuscript and no images were manipulated using AI.

REFERENCES

1. Yanoff M, Duker J. Ophthalmology. 3rd ed. St. Louis, MO: Elsevier; 2008. p. 1453-4.
2. Gutiérrez MD, Zuluaga NA, Buitrago AP, Botero DA. Benign fibrous histiocytoma, case report. *Hematol Med Oncol* 2016;1:21-3.
3. Srikanth D, Devi V, Polishetty N, Singh D. Subcutaneous benign fibrous histiocytoma: Rare presentation on cheek-case report and review of literature. *J Maxillofac Oral Surg* 2016;15:282-6.
4. Chen TC, Kuo T, Chan HL. Dermatofibroma is a clonal proliferative disease. *J Cutan Pathol* 2000;27:36-9.
5. Skoulakis CE, Papadakis CE, Datselis GE, Drivas EI, Kyrmizakis DE, Bizakis JG. Subcutaneous benign fibrous histiocytoma of the cheek. Case report and review of the literature. *Acta Otorhinolaryngol Ital* 2007;27:90-3.
6. Ceroni D, Dayer R, De Coulon G, Kaelin A. Benign fibrous histiocytoma of bone in a paediatric population: A report of 6 cases. *Musculoskelet Surg* 2011;95:107-14.
7. Fletcher CDM, Unni KK. World Health Organization classification of tumours pathology and genetics of tumours of soft tissue and bone. *Cancer* 2002;177:1365-76.
8. Henderson MT, Hollmig ST. Malignant fibrous histiocytoma: Changing perceptions and management challenges. *J Am Acad Dermatol* 2012;67:1335-41.
9. Von Mehren M, Benjamin RS, Bui MM, Casper ES, Conrad EU 3rd, DeLaney TF, *et al.* Soft tissue sarcoma, version 2.2012: Featured updates to the NCCN guidelines. *J Natl Compr Canc Netw* 2012;10:951-60.
10. Marback RL, Kincaid MC, Green WR, Iliff WJ. Fibrous histiocytoma of the lacrimal sac. *Am J Ophthalmol* 1982;93:511-7.

How to cite this article: Tenmang PE, Akpa PO, Kaigama Y, Dung SM. Benign fibrous histiocytoma of the lacrimal sac. *J Ophthalmic Res Pract.* doi: 10.25259/JORP_21_2024