

Photo Essay **Glaucoma**

The red blood-stained end-staged iris tissue!!!!

Isha Agarwalla¹, Mohit Garg² , Ramesh Agarwalla³

¹Department of Cataract, Oculoplasty, Drishti Netralaya, Dibrugarh, Assam, ²Department of Vitreoretina, Vivekananda Netralaya, Dehradun, Uttarakhand,

³Department of Cataract, Anterior Segment, Community Ophthalmology, Drishti Netralaya, Dibrugarh, Assam, India.



***Corresponding author:**

Dr. Isha Agarwalla,
Department of Cataract,
Oculoplasty, Drishti Netralaya,
Dibrugarh, Assam, India.

ishaagarwalla@gmail.com

Received : 29 March 2023

Accepted : 01 May 2023

Published : 17 June 2023

DOI

10.25259/JORP_10_2023

Quick Response Code:



A patient, 40-year-old man, came with complete loss of vision in the right eye. He has been a chronic diabetic, uncontrolled, and not under medications.

On examination, he had perception of light present in right eye (PL+) vision. On the slit lamp, his right eye was severely congested. Iris showed multiple blood vessels, both thick and thin creeping from the periphery to the pupillary margin. The vessels were present 360° around the iris tissue which made the pupil non-reactive with inferior synechiae. Intraocular pressure was 26 mm Hg, under medications [Figure 1]. Posterior segment revealed chronic retinal detachment on indirect examination.

This clinical picture gives a differential diagnosis of chronic retinal detachment, uncontrolled end-staged glaucoma, posterior segment tumors, and long-standing trauma to the eye.

Rubeosis iridis or iris neovascularization is characterized by proliferation of blood vessels over the iris surface, and it occurs in reaction to ischaemic change in retina. Common causes of rubeosis iridis are Proliferative diabetic retinopathy (PDR), central retinal vein occlusion, long-standing

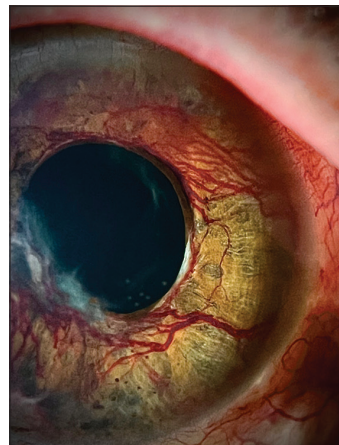


Figure 1: Iris showed multiple blood vessels, both thick and thin creeping from the periphery to the pupillary margin. The vessels were present 360° around the iris tissue which made the pupil non-reactive.

This is an open-access article distributed under the terms of the Creative Commons Attribution-Non Commercial-Share Alike 4.0 License, which allows others to remix, transform, and build upon the work non-commercially, as long as the author is credited and the new creations are licensed under the identical terms.

©2023 Published by Scientific Scholar on behalf of Journal of Ophthalmic Research and Practice

retinal detachment and ocular ischaemic syndrome.^[1] These new blood vessels start from the pupillary border and often involve trabecular meshwork. If left untreated, it leads to neovascular glaucoma.^[2] Rubeosis iridis, secondary to PDR are treated with panretinal photocoagulation.^[3] Role of anti - VEGF (vascular endothelial growth factor) injection has been described in rubeosis iridis.^[4]

The goal of any healthcare setup should be to prevent eyes from reaching this end-stage disease. Multiple level health-care professionals should come together and orient themselves toward the commonest eye conditions and their treatments in the early stage.

Declaration of patient consent

The authors certify that they have obtained all appropriate patient consent.

Financial support and sponsorship

Nil.

Conflicts of interest

There are no conflicts of interest.

REFERENCES

1. Pagoulatos D, Georgakopoulos C. Rubeosis iridis. Pan Afr Med J 2017;28:279.
2. Available from: <https://morancore.utah.edu/section-10-glaucoma/neovascularization-of-the-iris-rubeosis-iridis> [Last accessed on 2019 Jul 13].
3. Reháč J. Rubeosis iridis and neovascular glaucoma: I. Etiopathogenesis and treatment--the present state of the problem. Acta Univ Palacki Olomuc Fac Med 1992;134:101-3.
4. Davidorf FH, Mouser JG, Derick RJ. Rapid improvement of rubeosis iridis from a single bevacizumab (Avastin) injection. Retina 2006;26:354-6.

How to cite this article: Agarwalla I, Garg M, Agarwalla R. The red blood-stained end-staged iris tissue!!!!. J Ophthalmic Res Pract 2023;1:44-5.